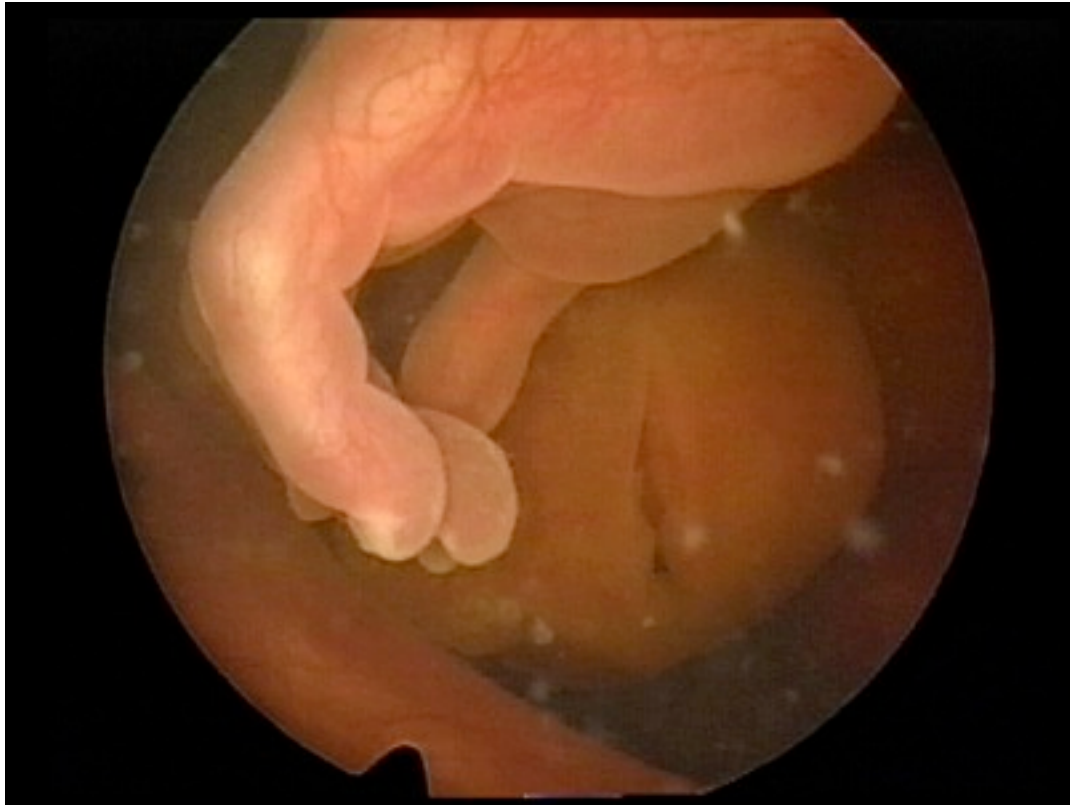


TTTS: Twin-twin transfusion syndrome

FETOSCOPIC LASER SURGERY



FETUS UNDERGOING FETOSCOPIC LASER SURGERY



Perinatology, Fetal Diagnosis & Therapy

Maternal and Perinatal Care Center,

Seirei Hamamatsu General Hospital

Takeshi Murakoshi, MD PhD

e-mail: t-murakoshi@sis.seirei.or.jp



Table of Contents

Diagnosis of Twin-Twin Transfusion Syndrome	1
What is twin-twin transfusion syndrome?	1
Diagnostic criteria of twin-twin transfusion syndrome	1
Clinical conditions of twin-twin transfusion syndrome	2
Classification of severity (stage) of TTTS (Quintero’s Stage)	5
How the death of one fetus affects the survivor	5
Treatments of Twin-Twin Transfusion Syndrome	6
Methods for treating twin-twin transfusion syndrome	6
Amnioreduction (AR)	6
Fetoscopic Laser Surgery (FLP: fetoscopic laser photocoagulation of communicating vessels)	6
Indications and summary for FLP	7
Techniques of procedure (method)	7
Conducting the procedure	8
Complications and Adverse Effects	9
Expected therapeutics effects	10
Other therapies	11
Outcomes of Fetoscopic Laser Surgery	12
Results achieved at Seirei Hamamatsu General Hospital Maternal and Perinatal Care Center	12
Comparison of results in Japan to results in other countries	12

Results by severity (stage) of disease (comparison of amnioreduction and laser surgery)	13
When undergoing Fetoscopic Laser Surgery	14
Publication of treatment results	14
Costs	14
Initial consultation	14
Consent Form	15
What You Should Know Regarding Twin Pregnancies	16
Diagnosis of zygosity and chorionicity	16
General risks in twin pregnancies (particularly the risk of premature labor)	17
Risks with monochorionic twins	18
Risk of one fetal demise in the case of monochorionic twins	18
Risk of neurological sequelae in twins	18
Reference	19

Diagnosis of Twin-Twin Transfusion Syndrome

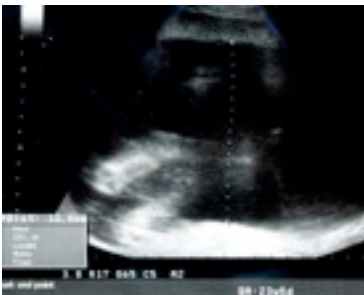What is twin-twin transfusion syndrome?

Twin-twin transfusion syndrome (TTTS) is a specific condition that only occurs in multiple pregnancies of monozygotic (monochorionic) twins. When twins share a single placenta (monochorionic twins), the blood vessels become mutually interconnected in the placenta, so that blood flows back and forth between both twins. Normally a balance is reached in the blood flow between each twin and pregnancy progresses without problems. TTTS occurs when an imbalance arises and blood flows disproportionately to one twin or the other. If the condition progresses and becomes severe, generalized swelling can occur in the twin receiving the surplus blood (recipient), which can lead to heart failure and hydrops fetalis. Polyhydramnios also occurs due to increased fetal urinary output. On the other hand, the twin outputting more blood (donor) remains small and underdeveloped, and the resulting decrease in urinary output can lead to renal failure and oligohydramnios. Early-onset severe cases occur in 5-10% of monochorionic twins, and infant mortality is virtually 100% without treatment. Polyhydramnios of the recipient twin causes an increase in the size of the uterus, which can lead to miscarriage and the inability to continue pregnancy to term, and increases the potential for premature delivery.

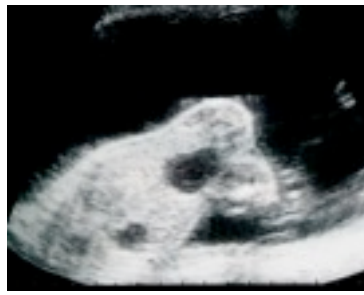Previously, amnioreduction was the only treatment available for severe TTTS. However, at our clinic (Maternal and Perinatal Care Center of Seirei Hamamatsu General Hospital), we have been able to provide a new therapy for patients diagnosed with TTTS since 2002, involving photocoagulation of placental vascular anastomoses using a fetoscope and a medical laser. This useful procedure is currently the first-line therapy used in Europe and North America to treat severe TTTS, having replaced amnioreduction.

Diagnostic criteria of twin-twin transfusion syndrome

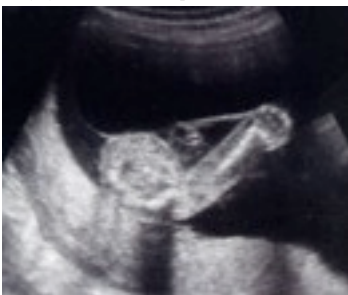The criterion used to diagnose TTTS is the simultaneous occurrence of polyhydramnios due to polyuria with oligohydramnios due to oliguria. This assumes that diseases causing polyhydramnios and oligohydramnios (such as premature rupture of the membranes, abnormality of the urinary system and intestinal atresia) have been excluded.



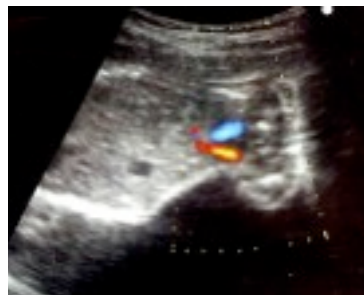Polyhydramnios of recipient twin (>8 cm)



Enlarged bladder in recipient twin due to polyuria



Oligohydramnios of donor (<2 cm)



Bladder is extremely small or not visible

Ultrasonography reveals a condition in which there is virtually all amniotic fluid (completely black) Bladder is large and prominent.

Donor can be seen stuck against the uterine wall and placenta (stuck twin). In this condition, the membrane separating the two fetuses is plastered on the donor fetus and is thus difficult to see. This situation could be mistaken for monoamniotic twins. The bladder is small and virtually invisible.

TTTS is diagnosed when the following conditions are met, and this therapy is inapplicable under any other conditions.

✓Twins must be monochorionic and diamniotic.

- The chorionicity of the twins should be diagnosed by ultrasonography in the first trimester of pregnancy. As this condition never occurs in dichorionic twins, the diagnosis of chorionicity is extremely important.
- If chorionicity is not diagnosed in the first trimester, diagnosis will be based on the number of placentas (one), membrane thickness (very thin), and genders of the twins (same gender).

✓Polyhydramnios and oligohydramnios must be present simultaneously.

- Polyhydramnios is present if ultrasonography shows a maximum amniotic fluid depth ≥ 8 cm, and a large distended fetal bladder (polyuria)
- Oligohydramnios is present if ultrasonography shows an amniotic fluid depth ≤ 2 cm, and the fetal bladder appears small or is not visible (oliguria, anuria).

✓Other diseases that cause polyhydramnios/oligohydramnios must be excluded.

- Polyhydramnios: fetal intestinal atresia, or stenosis, difficulty swallowing, neural tube defect, etc.
- Oligohydramnios: rupture of the membranes, urethral atresia, renal agenesis, etc.

✓Differences in body weight, abdominal circumference, and cardiac function are considered, but are not diagnostic criteria.

- The classical diagnostic criterion used to be a body weight difference of $\geq 25\%$ (estimated weight or birth weight). However, this is not essential to the condition of TTTS and is not used in the current diagnostic criteria. However, this finding is considered as a symptom of TTTS in the diagnosis.
- The strict diagnostic criterion for TTTS is polyhydramnios/oligohydramnios. Fetal cardiac dysfunction (cardiomegaly, tricuspid regurgitation, etc.) are also symptoms of TTTS (particularly in the recipient twin), but are not used as diagnostic criteria.

✓Discrepancy between twins in hemoglobin levels is not used in the diagnosis.

- Although this was included in the classical diagnostic criteria, frequently no difference is apparent between the twins with regard to hemoglobin levels, and thus this is not used in the current diagnostic criteria (criteria for prenatal ultrasonographic diagnosis).

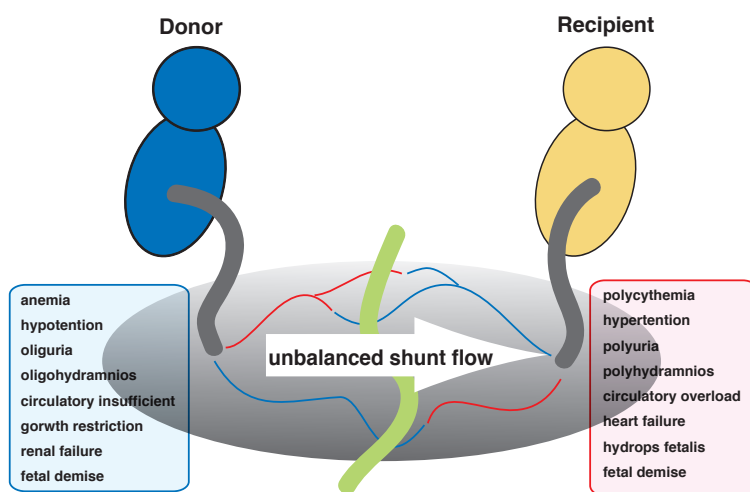
Clinical conditions of twin-twin transfusion syndrome

TTTS is believed to occur in 10-15% of monochorionic diamniotic (MD) twins. MD twins share one placenta, and several anastomoses (connected blood vessels) are always present (normally 7-8 vessels). Normally, because a balance exists in the blood flowing between the twins through the anastomoses, no problems arise because blood is flowing back and forth between the twins (originally the same blood).

However, TTTS occurs if for some reason this balance collapses and overall blood flow tends to be in one direction.

The donor (twin from whom blood disproportionately flows out) enters a state of anemia, and hypotension, oliguria (urine production decreases due to insufficient blood flow to the kidneys), and oligohydramnios occur due to generalized insufficient blood volume (because most of the amniotic fluid is comprised of fetal urine, amniotic fluid levels decrease as urinary output decreases). Fetal growth is also restricted, resulting in a condition called intrauterine growth restriction (IUGR). This condition will result in poor blood circulation that will eventually lead to renal failure and fetal demise due to circulatory failure. Conversely, the recipient (the twin receiving surplus blood) will enter a state of polycythemia due to excessively high blood volume, leading to hypertension and putting great stress on the heart. This gradually results in a condition of polyuria with increased urinary output in an attempt to reduce blood volume, progressing rapidly to polyhydramnios in response. In this condition, poor circulation continues to advance, affecting the fetal hormones and endocrine actions. Moreover, because the urine that is produced is diluted, the high osmolality blood (blood thickens) received increases, and moisture drawn in from the mother through the placenta can further contribute to a deterioration of conditions (extreme thirst in the mother can occur as a result of rapid enlargement of the uterus and a tendency toward dehydration). Longterm continuation of this condition puts a great deal of stress on the heart of the baby, which will eventually lead to cardiac failure followed by hydrops fetalis (generalized swelling, pleural effusion and accumulation of ascites), which can result in fetal demise. TTTS is not a disease of one twin or the other, but is characterized by conditions becoming worse for both twins.

Regardless of the condition of the babies, it is important to be aware that if severe polyhydramnios occurs, uterine contractions (labor pain) may intensify, and membranes can rupture leading to miscarriage or premature delivery.



Progression of TTTS



normal amniotic fluid volume



amniotic fluid volume discordance

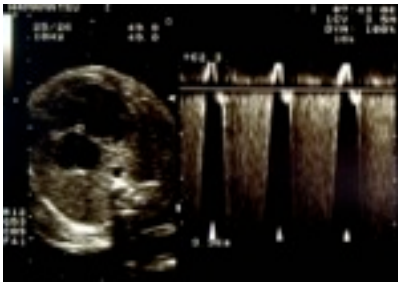


poly-/oligohydramnios

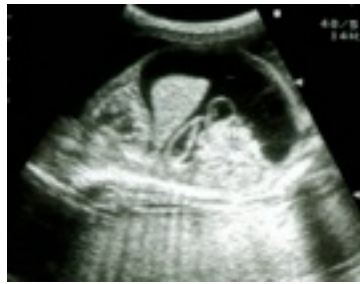

stuck twin

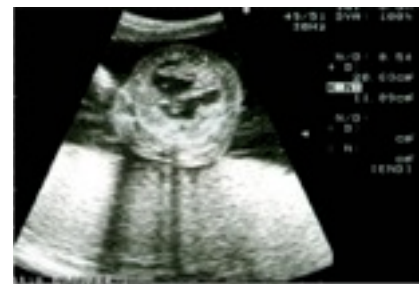Changes in cardiac function of recipient twin



tricuspid regurgitation



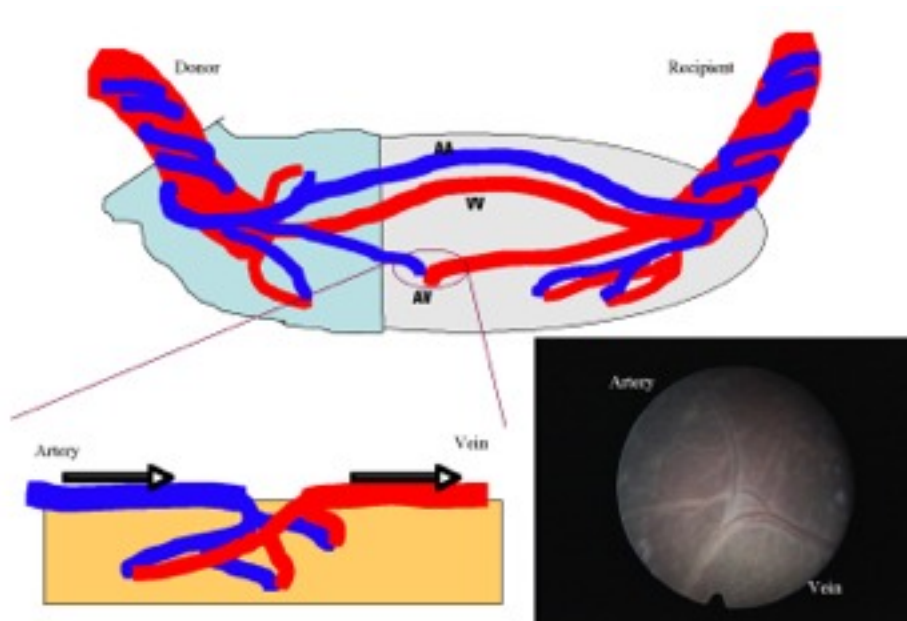
accumulation of ascites



cardiomegaly and thick placenta

Increased stress on the recipient's heart can lead to a condition of fetal cardiac failure, and symptoms such as cardiomegaly, atrioventricular valve regurgitation (tricuspid valve regurgitation, mitral valve regurgitation), pleural effusion, and ascites can occur. The placenta becomes engorged and appears thick.

Placental anastomoses



Blood from the fetuses enters the placenta through the umbilical cord (arteries), receives oxygen and nutrients from the mother through the placenta, and returns to the fetus via the umbilical cord (vein). However, in the case of monozygotic twins, after receiving oxygen and nutrients in the placenta, an artery from one of the twins may return not to the same twin, but to the other twin instead. This is called an anastomosis (arterial-venous anastomosis). Venovenous and arterio-arterial anastomoses can also occur, via veins directly connected to other veins or arteries directly connected to other arteries.

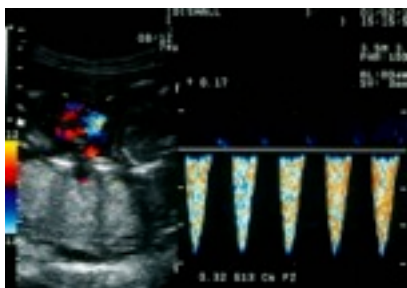
Normally, a balance in blood flow will be maintained, but TTTS will occur if this balance is disrupted. All anastomoses can be confirmed by observing the surface of the placenta.

Classification of severity (stage) of TTTS (Quintero's Stage)

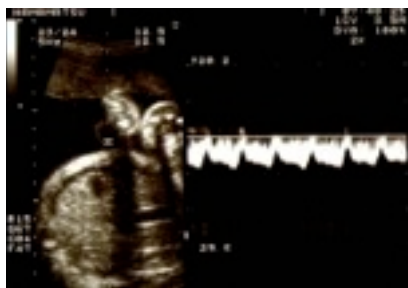Quintero's classification is generally used to classify TTTS severity in stages, as follows:

- Stage I The bladder of the donor twin is still visible. Fetal blood flow is also normal.
- Stage II Bladder of donor twin is not visible.
- Stage III The following blood flow abnormalities appear in either twin
 - Absent or reversed end-diastolic flow in the umbilical artery
 - Pulsatile umbilical venous flow
 - Reverse flow in ductus venosus
- Stage IV Presence of hydrops fetalis in either fetus
- Stage V Fetal demise

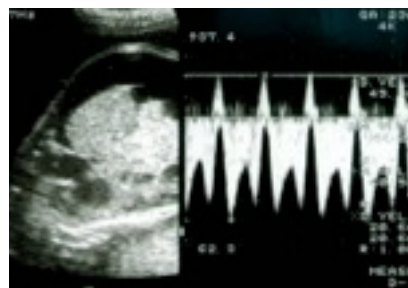
*If fetal blood flow abnormalities are present when the bladder is still visible, this is classified as Stage III atypical, distinguishing this situation from Stage III classical where the bladder is not visible.



Absent or reversed end-diastolic flow of umbilical artery



Pulsatile umbilical venous flow



Reverse flow in ductus venosus

How the death of one fetus affects the survivor

With all MD twins, not just those with TTTS, the effects of the death of a twin are substantial, and the remaining twin may also die, or even if the baby does survive, the possibility of neurological sequelae is reportedly around 30-40%. In particular, blood may continue to flow from the surviving fetus through the placental anastomoses to the dead fetus.

Treatments of Twin-Twin Transfusion Syndrome

Methods for treating twin-twin transfusion syndrome

If the cause of TTTS is an imbalance blood distribution in the shared placenta through anastomoses, then it logically follows that TTTS can be cured after removing the cause. Consequently, if this condition is present at a time when extrauterine survival is possible, the most basic treatment is to induce delivery and perform standard neonatal care.

Amnioreduction (AR)

The objective of this treatment is to ameliorate maternal symptoms (pressure symptom, uterine contraction, etc.) to allow the pregnancy to continue by intervening to remove amniotic fluid from the polyhydramniotic recipient twin. Although reducing intrauterine pressure could potentially improve circulation, in reality this is not curative treatment for TTTS, as the primary objective has prolonged pregnancy. As a result, the prognosis is determined by the gestation age (weeks) at the time of delivery and the severity (stage).

While observing the fetuses, umbilical cord, placenta and amniotic fluid using ultrasound, a local anesthesia is administered, an amniocentesis needle (<1 mm) is inserted into the uterus, and amniotic fluid is extracted until the amniotic sac returns to normal. In the case of severe TTTS, treatment is almost never completed with one procedure, and amniotic fluid is repeatedly extracted as it continues to accumulate. AR will be required once or twice a week.

The survival rate of the fetuses is 50-60%, with neurological sequelae reported in 20-25% of cases. As anastomoses are present between the twins, when one dies neurological sequelae are reported in the survivor in 30-40% of cases. As AR does not constitute radical therapy for TTTS, the survival rate falls and sequelae increase as the severity (stage) increases.

Fetoscopic Laser Surgery (FLP: fetoscopic laser photocoagulation of communicating vessels)

The curative treatment of TTTS is to make the circulatory systems of the twins completely independent of each other by photocoagulating the placental anastomoses, which are the cause of TTTS. This procedure was first reported by Dr. DeLia and his team in 1990 in the U.S. Later in 1995, teams led by Dr. DeLia in the U.S. and Dr. Ville in France separately reported results of this therapy, but at that time no conclusions had been made with regard to whether fetoscopic laser surgery was superior to amnioreduction. In 1999, Dr. Hecher of Germany compared amnioreduction and laser therapies, and although no differences were found in survival rates, laser photocoagulation was identified as a promising therapy with the ability to reduce neurological sequelae. Also in 1999, Dr. Quintero's team in Florida in the U.S. proposed a system for classifying TTTS by severity (stage), and in 2003, reported that laser surgery led to better survival rates and neurological sequelae outcomes than amnioreduction in the case of severe (stage III and IV) TTTS. In 2004, the Eurofetus study group, based on the results of a randomized study, concluded that laser surgery was superior to amnioreduction therapy for all stages of TTTS with respect to survival rates and neurological sequelae. As a result, laser surgery is now considered the first-line therapy for treating severe TTTS.

In Japan, the first patient was treated at Keio University Hospital in 1992, but this procedure was not repeated in Japan for the next 10 years. From 2001 to 2002, Dr. Murakoshi of the Seirei Hamamatsu General Hospital, Maternal and Perinatal Care Center was in Florida in the U.S. to study under Dr. Quintero, where he learned the techniques of fetoscopic laser therapy before returning to Japan. After a period of preparation, since July 2002, when the first actual fetoscopic laser treatment was performed at Seirei Hamamatsu General Hospital, this laser surgery has been performed in over 160 patients (as of July 2011). Moreover, this therapy has begun to be performed by other

physicians who have learned the technique, at the National Center for Child Health and Development (Tokyo) since February 2003; Yamaguchi University Hospital since February 2004 (not available now); Niigata University Hospital since May 2004 (not available now); Nagara Medical Center (Gifu) since December 2005; Miyagi Children Hospital since 2009, Osaka Medical Center and Research Institute for Maternal and Child Health since 2010, and Tokuyama Chuo Hospital since 2010. These institutions have joined together to form the Japan Fetoscopy Group, which is currently is involved in joint research on techniques, and analyzes and reports on results.

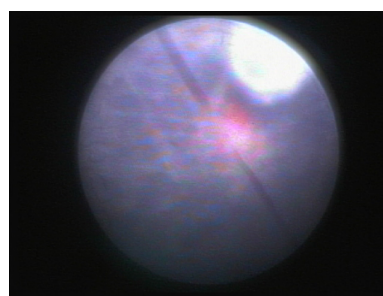
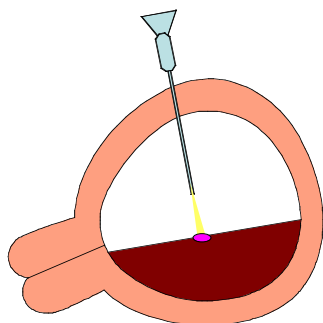
Indications and summary for FLP

Even when TTTS is diagnosed, the procedure is not performed for all patients. The following conditions must be met for a patient to be eligible for this procedure.

- I. Stage I to IV TTTS
- II. Gestational age less than 26 weeks
- III. Membrane must be intact and not ruptured
- IV. No amniorrhexis or detachment of the amnion
- V. There should be no clear signs of threatened abortion or threatened premature labor (in principle, cervical length should be at least 20 mm).
- VI. No severe fetal malformations
- VII. The mother is able to withstand surgery (no serious co-morbidities)
- VIII. Mother has no infectious disease that can be transferred mother-to-child (contraindicated for HIV, negotiable in cases involving HB or HCV).
- IX. Patient understands that this therapy is investigational and consents to undergoing treatment.

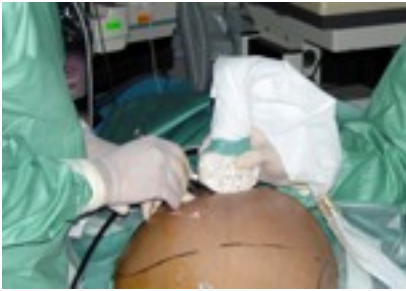Techniques of procedure (method)

After adequate anesthesia for mother and fetuses, a 4-mm skin incision is made in the abdominal wall of the mother, and a wide (3.8 mm) syringe (trocar) is inserted into the amniotic sac of the recipient fetus. An endoscope (fetoscope) is inserted through the trocar and all anastomoses on the surface of the placenta are located. The anastomoses are then coagulated using a medical laser inserted through the endoscope. After all anastomoses have been coagulated, amniotic fluid is extracted and the procedure is completed. Most procedures can be performed with a single trocar, but in rare cases an additional trocar becomes necessary.

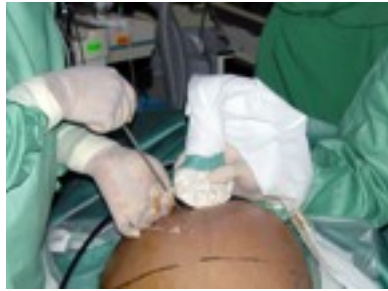

Normally, epidural anesthesia is performed to eliminate pain in the abdomen where the needle is inserted. As the patient is conscious, she is able to view the procedure on a monitor. However, depending on the condition of the mother, general anesthesia, spinal anesthesia, or local anesthesia may also be used. This procedure becomes difficult to perform if the fetuses are moving. Consequently, the fetuses are also anesthetized if necessary.

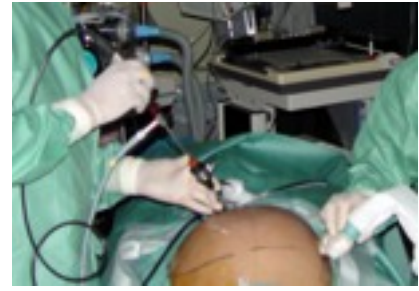Conducting the procedure



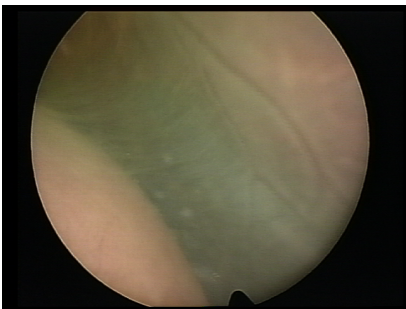
4mm skin incision



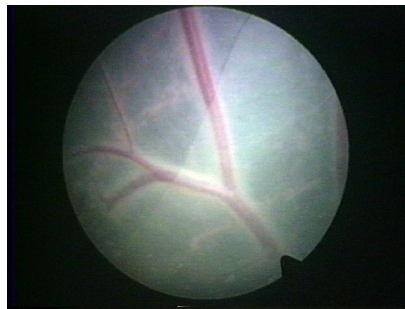
insert the 3.8 mm trocar to the uterus



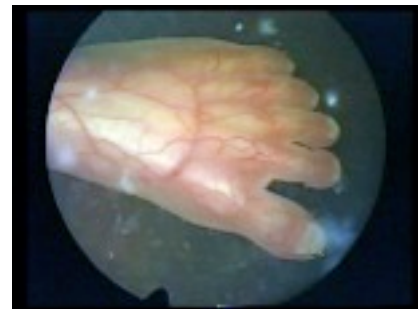
3.5 mm fetoscope inserted through trocar



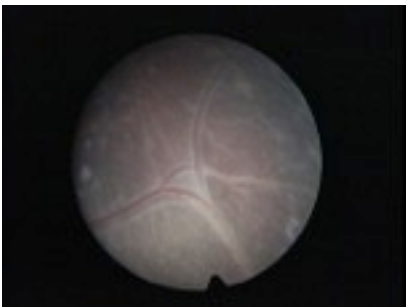
stucking membrane against the donor




blood vessels can be seen through the membrane



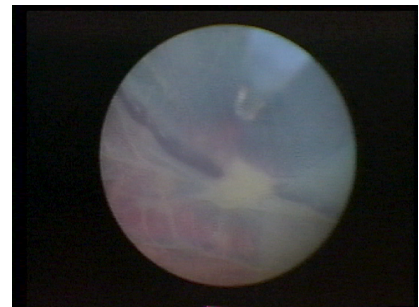
fetal foot



anastomotic vessels



laser shot to the vessels



coagulated vessels

Complications and Adverse Effects

This procedure believes to be the primary therapy in Europe, North America and Japan, but is not so established that it can be performed at any hospital. Although this procedure is performed in such a way as to ensure patient safety at all times, on rare occasions the following complications or adverse effects can occur.

1. It may not be possible to perform the procedure if bleeding occurs in the amniotic sac, or when the position of the placenta or fetus makes the procedure technically difficult. For example, if the amniotic fluid has become murky with blood from an earlier amniocentesis, the procedure becomes difficult to perform because good visibility cannot be assured.
 - Although every measure will be taken to continue the procedure (including recirculation of the amniotic fluid and changing fetal position, etc.), the procedure may be discontinued if continuation of the procedure is determined to be dangerous to the health of the mother or fetuses, or if the procedure is expected to have to be abandoned unfinished due to extreme difficulty in completion (1-2%).
2. Fetal demise may occur if bleeding from vessels on the surface of the placenta takes place and cannot be stopped.
 - The procedure is performed with meticulous care so that bleeding does not occur. However, if such an occurrence, maximum efforts will be made to stop the bleeding, but if significant bleeding into the amniotic sac occurs, visibility may become difficult to maintain and the procedure may become impossible to perform (less than 1% of cases).
3. Fetal (neonatal) brain damage (maximum 5%) or other fetal complications can occur. These can exist before performing the procedure, or may also manifest as a result of the underlying disease and be unrelated to the procedure. These conditions are impossible to ascertain before procedure.
 - Laser surgery can only improve TTTS and complications associated with single fetal demise. This procedure is not performed to treat prematurity, problems at the time of delivery or diseases other than the underlying TTTS. Following the procedure the general prognosis (results) will be no different from for normal MD twins.
4. Following the procedure, miscarriage/premature delivery, threatened abortion/premature delivery, and rupture of membranes can occur. A tocolytic agent will be administered for prophylactic purposes.
 - Very early in the pregnancy (gestational weeks 16 to 17), the amnion may not be fully adherent to the uterine wall, increasing the risk of membrane rupture. Unlike normal membrane rupture, this type can heal over time without intervention.
5. On rare occasions, the uterus or the fetus can become injured, but because the procedure is performed under ultrasonographic and endoscopic guidance, this occurs very rarely under normal circumstances.
6. On rare occasions, during the procedure bradycardia can occur in one of the fetuses. Even in irreversible cases, the procedure will be completed because the goal is to prevent twin-to-twin transfusion, and not to enable extrauterine fetal treatment.
 - If the procedure is completed (all anastomoses have been coagulated and circulation in each twin is completely independent of the other), there is no logical reason that the survivor should be affected. Although we would like to save both twins, even in a worst-case scenario it is possible to prevent adverse effects on the survivor.
7. Bleeding from the uterine wall at the trocar insertion site can normally be stopped by applying pressure. However, on rare occasions when hemostasis is difficult to attain, an incision in the skin may be made and the area in the uterine wall where the bleeding is located may be sutured. Transfusion may also be performed if bleeding is excessive.
 - Laparotomy and transfusion are needed in less than 1% of cases.
8. In extremely rare cases when it is impossible to control bleeding, a hysterectomy may be required.
 - This does not occur with any particular frequency with this procedure (laser surgery), and may also occur with any intrauterine procedure including amnioreduction, etc., or with normal delivery (around 0.01%).

9. In extremely rare events, during surgery or post-operatively, a condition known as pulmonary edema can occur in which excessive amounts of fluid accumulates in the lungs.

→ By adjusting the volume of intravenous infusion before surgery and carefully controlling anesthesia, severe pulmonary edema has become extremely rare (less than 1%).

10. On very rare occasions, post-operative vein thrombosis or pulmonary thromboembolism can occur.

→ This does not occur with any particular frequency with this procedure (laser surgery), and though rare, may also occur with any kind of surgical procedure. Preventive measures taken include the use of elastic stockings and early postoperative ambulation (less than 1%).

*Other complications may occur even if amnioreduction therapy is implemented or this procedure is not conducted. If any of these unanticipated abnormalities should occur, the best medical treatment will be provided, depending on the conditions present.

Expected therapeutics effects

If treatment is successful, pregnancy should be able to be continued and fetal prognosis should improve. Specifically, from the maternal perspective, there is a 90% probability that at least one fetus will survive, and a 66% probability that both will survive. From the perspective of the baby, the survival rate is 80%, with neurological sequelae in a maximum of 5% of survivors. Untreated, the probability of fetal demise is virtually 100%. Moreover, with amnioreduction therapy only, although prognosis will vary, results are poorer in all stage TTTS than with laser surgery).

Most cases of fetal demise occur within 24 h of the procedure. Two weeks after the procedure, few confirmed complications occur in either mother or child. Laser surgery eliminates the jointly shared placenta with the objective of creating mutually independent circulation for each twin. As a result, depending on circumstances, the postoperative placental area can become considerably reduced in size. The original area of the placenta, with current medical practice, cannot be increased, and is impossible to predict preoperatively. As a result, if the area of the placenta is not large enough to sustain life itself after the procedure, fetal demise will unfortunately occur. This is believed to be the cause in about 80% of cases resulting in fetal death. In addition, even when laser surgery is able to eradicate the cause of TTTS, the cardiac function, etc., of the fetus can become overstressed, which can become irreversible and untreatable (resulting in fetal death), with apparently little correlation with TTTS severity. In the unfortunate event of the demise of one fetus, because the circulation of the surviving fetus is now completely independent, the probability of residual sequelae, etc., is now theoretically the same as with dizygotic twins. Moreover, continuation of the pregnancy is not a problem.

If postoperative recovery occurs without complications, normally within 1 week of the procedure the bladder of the donor will return to normal size, and the amniotic sac will also be close to normal. Most blood flow abnormalities improve within 1 week. In the recipient twin, polyhydramnios will no longer progress after the procedure is completed, and urinary output and amniotic fluid volume will gradually decrease. Normally after about 2 weeks, conditions will have normalized in most cases, including blood flow abnormalities.

Other therapies

The following therapies are currently also available instead of laser surgery.

✓ Expectant management (wait and see approach)

- In this situation, the fetal condition is monitored under ultrasound, and tocolytic treatment is used to prevent premature labor. In the case of severe TTTS, this therapy will result in preterm delivery virtually 100% of the time, and prognosis for the infants is poor.

✓ Amnioreduction

- Amniotic fluid is aspirated from the recipient twin (polyhydramniotic twin) to prevent preterm delivery. Depending on the case, this therapy will also increase the amniotic fluid of the donor (oligohydramniotic twin). Normally this procedure must be repeated several or even dozens of times. With this therapy, the probability of survival of at least one twin is 66%, with neurological sequelae observed in 15-25% of cases.

✓ Amniotic septostomy (Disruption of dividing membrane)

- During amnioreduction, the membrane between the two fetuses (amnion) is pierced to make a pathway between the amniotic sacs of the twins. The therapeutic effect of this procedure has yet to be established, as there are reports of results being superior to amnioreduction as well as other reports that results are no different from amnioreduction. Entanglement of the umbilical cords of both twins resulting in fetal demise has been reported as an adverse event of this procedure.

✓ Termination of pregnancy

- If the patient does not want to continue the pregnancy, and it is legally possible based on the gestational age, one option is to artificially terminate the pregnancy. In principle, abortions are not performed at this hospital.

The selection of any of these treatment options will be completely voluntary. We believe that the best treatment for severe TTTS is laser surgery.

Outcomes of Fetoscopic Laser Surgery

Results achieved at Seirei Hamamatsu General Hospital Maternal and Perinatal Care Center

Laser surgery was performed on 118 patients between July 2002 and December 2008. Based on the results from 92 patients who have delivered to date (maximum follow-up: 6 years), there has been a 78% survival rate, 3% abortion rate, and 5% rate of neurological sequelae. The survival rate without sequelae is 73%. From a maternal perspective, both fetuses survived in 64% of cases, with only one fetus surviving in 28% of cases. Demise of both fetuses has occurred in 8% of cases (in 92% of cases, at least one fetus survived). Complications were as follows; untreatable case due to placental and fetal position occurred in 1 patient; blood transfusion and hemostasis requiring laparotomy was necessary in 2 patients; intraoperative pulmonary edema developed in 1 patient; and delivery or miscarriage within 48 hours of the procedure occurred in 3 patients. However, no maternal residual sequelae occurred in any of these cases. Mean gestational age at the time of treatment was 21 weeks, and mean gestational age at the time of delivery was 32 weeks. A characteristic of our center is that we receive many referrals for patients with more severe TTTS. As a result, 17% of the procedures we have performed have been stage IV, and 63% stage III.

Survival rate according to the Stgae (Seirei Hamamatsu Hospital, 2010)

	SURVIVORS	SURVIVAL RATE%	NEUROLOGICAL SEQUELAE	NEUROLOGICAL SEQUELAE %
stage I (n=18)	19/36	81%	1/29	3.4%
stage II (n=28)	41/56	73%	4/41	9.8%
stage III (n=79)	128/158	81%	4/128	3.1%
stage IV (n=23)	37/46	80%	2/37	5.4%
total (n=148)	235/296	79%	11/235	4.7%

Comparison of results in Japan to results in other countries

Although laser surgery in Japan began about 10 years after the practice was started in Europe and North America, results have in no way been inferior. Our Japan Fetoscopic Group (JFG) and our center have achieved thoroughly satisfactory results for the treatment of TTTS.

Perinatal outcomes compared to Japan and other countries

	HECHER	QUINTERO	SENAT	HUBER	JAPAN	SEIREI
	1999 (n=73) Germany	2003 (n=95) USA	2004 (n=72) France	2006 (n=200) Germany	2006 (n=131) Japan	2010 (n=148) Our Center
2 survivors	42%	44%	36%	60%	65%	63%
1 survivor	37%	38%	40%	20%	27%	30%
≥1 survivor	79%	83%	76%	84%	92%	93%
survival rate	61%	64%	56%	72%	78%	79%
miscarriage	9%	8%	17%	4%	4%	3%
Delivery	33 weeks	32 weeks	33 weeks	34 weeks	32 weeks	32 weeks
Sequelae	6%	4%	7%	6%	5%	4%

Results by severity (stage) of disease (comparison of amnioreduction and laser surgery)

Amnioreduction is not a disease-modification therapy for TTTS. As a result, survival rates decrease and sequelae increase with the severity of the condition. However, even in severe cases, laser surgery achieves better results than amnioreduction with regard to survival rates and sequelae.

Comparison of fetal outcomes of amnioreduction and laser surgery (Quintero RA. 2003)

Stage	AMNIOREDUCTION (N=156)			LASER SURGERY (N=190)		
	death	survival	sequelae*	death	survival	sequelae*
I	1	21 (95.5%)	0 (0%)	10	32 (76.2%)	0 (0%)
II	8	38 (82.6%)	4 (8.7/10.5%)	23	47 (67.1%)	1 (1.4/2.1%)
III	30	24 (44.4%)	15 (27.8%/62.5%)	27	29 (51.8%)	2 (3.6/6.9%)
IV	27	7 (20.6%)	4 (11.8/57.1%)	8	14 (63.6%)	1 (4.5/7.1%)
total	66	90 (57.7%)	23 (14.7/25.6%)	68	122 (64.2%)	4 (2.1/3.3%)

* Cerebral palsy, mental retardation and periventricular leukomalasia (rate of total fetus % / rate of survival fetus %)

Survival rate after laser surgery according to Stage (Huber A, 2006)

	0 SURVIVOR	1 SURVIVOR	2 SURVIVORS	1 ≥ SURVIVOR
stage I (n=29)	6.9% (2/29)	17.2% (5/29)	75.9% (22/29)	93.1% (27/29)
stage II (n=81)	17.3% (14/81)	22.2% (18/81)	60.5% (49/81)	82.7% (67/81)
stage III (n=80)	17.5% (14/80)	28.7% (23/80)	53.8% (43/80)	82.5% (68/80)
stage IV (n=10)	30% (3/10)	20% (2/10)	50% (5/10)	70% (7/10)

When undergoing Fetoscopic Laser Surgery

Publication of treatment results

This treatment procedure is still in the experimental stage. Consequently, after protecting patient privacy (anonymity), treatment result data, images taken during the procedure, and data on the prognosis of the children (follow-up) will be published on our website and scientific literatures, and presented at foreign and domestic academic meetings.

Costs

Currently, fetoscopic laser surgery is not covered by insurance in Japan. However, because our center is a licensed provider of “advanced medical technology,” except for the cost of the laser surgery, all other costs will be covered by insurance. As a result, patients will need about 400,000 yen for surgical fees, but the other hospitalization expense will in principle be covered by insurance. The total cost will vary depending on the length of hospitalization, so please ask the attending physician.

Initial consultation

After an appointment has been set up (the day and time of the appointment will be set by your personal physician and an attending physician at our facility), you will bring a referral letter from your personal physician to the Obstetrics Department, where you will be seen as an outpatient. Your husband must also be present at that time, as explanations will need to be provided not just to you the patient, but also to the husband. Moreover, after conditions have stabilized following the procedure (usually after about 2 weeks), you will be transferred back to the hospital from which you were originally referred. Consequently, as a general rule, we only accept referrals from regional perinatal centers.

Day of surgery

On the day of surgery, an anesthesiologist will explain the anesthesia. As details of the procedure will be discussed after surgery, your husband must also be present at the hospital on the day of surgery.

Other

- This treatment has been approved by the Clinical Research Review Subcommittee and the Institutional Review Board of Seirei Hamamatsu General Hospital. (June 26, 2002; July 15, 2002)
- Undergoing this procedure shall be completely voluntary. Confidentiality regarding the procedure will be strictly maintained.
- Even if you do not undergo this procedure, we will devote our best efforts in implementing any other treatment. Moreover, no penalties will be suffered regardless of the treatment option you choose.
- If you have any questions or concerns regarding the treatment do not hesitate to consult the attending physician.

Consent Form

The above information regarding twin-twin transfusion syndrome and fetoscopic laser surgery have been explained to me.

Date: _____ (Year / Month / Day)

Seirei Hamamatsu General Hospital Maternal and Perinatal Care Medical Center

Obstetrician: _____ (signature)

Anesthesiologist: _____ (signature)

Witness: _____ (signature)

Having been informed of the above information, I hereby consent to undergo fetoscopic laser surgery.

Date: _____ (Year / Month / Day)

Patient Name: _____ (signature)

Relationship ()

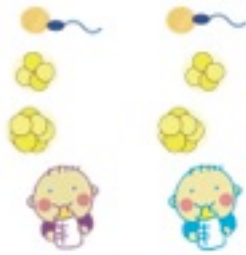
Name: _____ (signature)

What You Should Know Regarding Twin Pregnancies

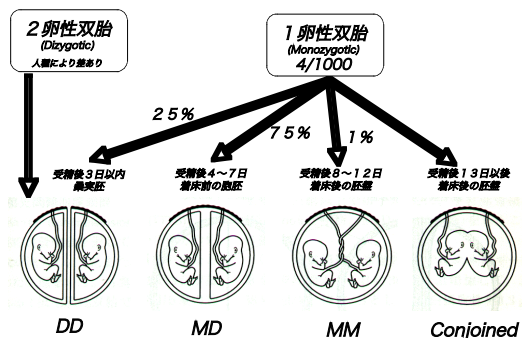
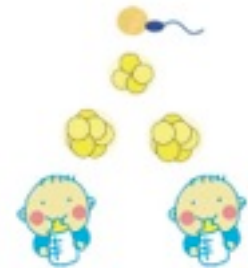Diagnosis of zygosity and chorionicity

A frequent topic of discussion in twin pregnancies is whether twins are monozygotic (identical) or dizygotic (fraternal). Most people’s knowledge of this extends only as far as an awareness that “monozygotic twins come from a single egg and resemble each other closely” while “dizygotic twins have two placentas and do not resemble each other.” This is true, of course, but we would like mothers and fathers of twins to understand a bit more.

One egg fertilized by a single sperm produces a single fertilized egg. The fertilized egg undergoes repeated division to eventually produce a single baby in the uterus. This process is exactly the same in both single and multiple pregnancies. Sometimes two fertilizations occur simultaneously, resulting in dizygotic twins that develop and grow together in the uterus. In other words, two siblings get along well together with each in the uterus until they are born on the same day. Consequently, they may or may not resemble each other (as ordinary siblings can also resemble each other as well). In addition, they may or may not have the same blood type, because they are siblings. Frequently, these twins have separate placentas, but when located very close to each the placentas can stick together (but since there are no shared blood vessels [anastomoses], there is no need for concern).

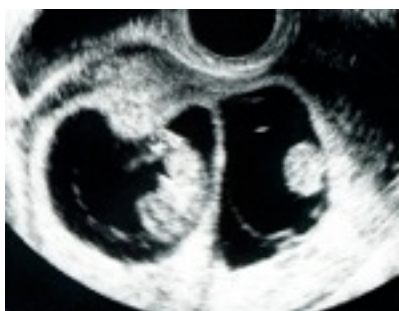

Monozygotic twins are fertilized in essentially the same way. A fertilized egg is produced from a single sperm in a single egg. Monozygotic twins occur when, during the process of cell division, the cells cleave into two separate embryos (a single egg is never fertilized by two sperm, and the egg does not divide into two). Monozygotic twins have the same basic genetic information, because when traced back to their origin they come from a single fertilized egg. As a result, they closely resemble each other (they are genetically identical). They also have the same blood type, and because their blood type is exactly the same, if by some chance it is needed, transplantation is possible to each other. Gender is also the same. However, due to environmental differences, this identical nature does not extend to their personalities. However, there does not only have to be just a single placenta. Depending on the time that splitting occurs, one or two placentae can develop.

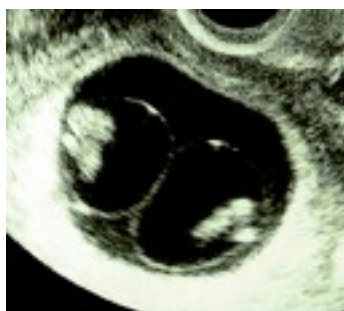

A singleton is always enclosed in two membranes (the chorion and amnion). With dizygotic twins, dichorionic/diamniotic twins (DD twins) will always result, because each twin has two membranes. When twins are monozygotic, different patterns occur depending on the time at which the cells cleaved into two individuals. DD twins occur within 3 days of fertilization; monochorionic/diamniotic (MD twins) between 4 and 7 days of fertilization; and monochorionic/monoamniotic (MM twins) between 8 and 12 days of fertilization. In other words, MD and MM twins will always be monozygotic, while DD twins may be monozygotic or dizygotic.

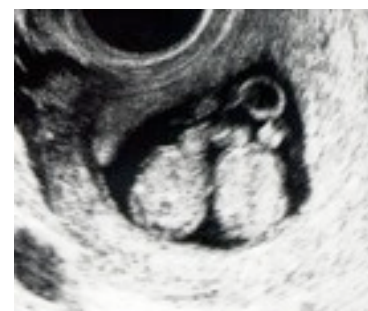Twin pregnancy risks are not only determined by zygosity (whether monozygotic or dizygotic), but are also determined by the nature of the membranes (DD, MD, or MM). As a result, it is important to diagnose chorionicity and amnionicity during the first trimester (around week 10 of gestation is ideal).



Dichorionic-diamniotic (DD) twin



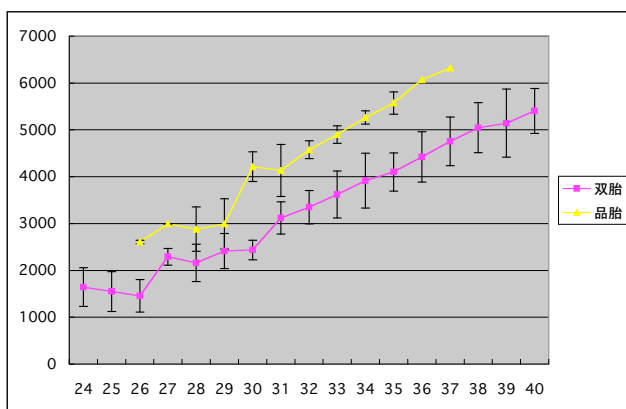
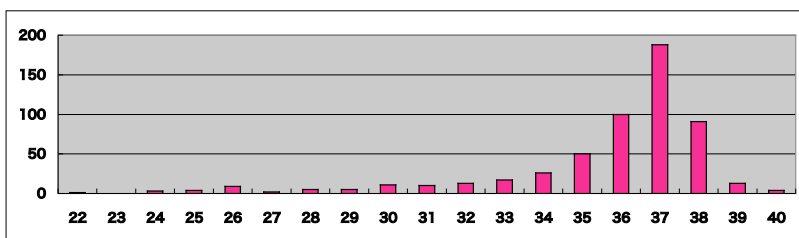
Monochorionic-diamniotic (MD) twin



Monochorionic-monoamniotic (MM) twin

General risks in twin pregnancies (particularly the risk of premature labor)

In twin pregnancies, because two babies are developing in a uterus that was originally meant for one, the risk of preterm labor (delivery of premature infant) is considerable. Delivery often occurs around 37 weeks of gestation, and few deliveries occur near the due date (40 weeks). Preterm labor at 36 weeks or less actually occurs in 45-50% of cases (almost half). Premature birth at less than 32 weeks, at which time a respirator is needed, occurs in about 11% of cases.



In a normal pregnancy, the mother will give birth to a baby weighing around 3 kg. If the total weight of the twins exceeds 3 kg, the uterus will fill up and labor pain may occur at any time. In reality, because the placenta and amniotic fluid is divided between the twins, uterine size will be at full term when each of the twins grows to 1.2-1.5 kg. Between weeks 28 and 32, the uterus of a pregnant mother with twins will be about the same size as at full term. However, this is still too early for birth. Please be careful.

If 30 weeks have passed, even without preterm labor or rupture of the membrane, the risks of pregnancy induced hypertension (preeclampsia) and fetal growth retardation (development of the baby is restricted) increase. From the initial stage of pregnancy, particularly during months 5 to 6 of gestation which everyone thinks of as a period of stability (at this point in time, your uterus has already increased to about the size seen in a singleton pregnancy at 8 to 9 months gestation), be aware that you and your baby must take it very easy.

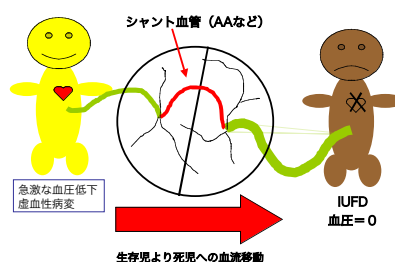
Risks with monochorionic twins

With dichorionic twins, regardless of whether they are monozygotic or dizygotic, the course of pregnancy will be monitored with a focus on preventing premature labor. However, if twins are monochorionic, more caution is necessary due to particular risks that occur only in monochorionic twins (although there is no need to panic, conditions must be monitored very carefully).

TTTS can occur in approximately 10-15% of monochorionic twins. If monochorionic diamniotic twins are diagnosed, medical check-ups will be performed every 2 weeks at least, and fetal and bladder size, amniotic fluid volume, and cardiac function (fetal blood flow, etc.) will be carefully monitored. If only slight variations are observed, the frequency of examinations will be increased and conditions will be cautiously followed. Differences in development of twins sometimes occur even not having TTTS (no observed polyhydramnios/oligohydramnios). Provided amniotic fluid volumes are in the normal range, there are no blood flow anomalies, and even if developmental differences are present, each baby shows reasonable development, no major problems should occur (even siblings do not have exactly the same birth weights after all). However, if one of the babies is very small, and a discrepancy in body weight of 25% or more is observed, a more prudent course of action becomes necessary. If TTTS does occur and developmental differences become marked, depending on the circumstances, hospitalization may become necessary.

Risk of one fetal demise in the case of monochorionic twins

If for some reason one monochorionic twin dies (passes away in the womb), blood can abruptly flow from the living twin to the dead twin through the interconnected blood vessels (anastomoses). This does not happen in all cases. Circumstances will vary depending on the type of anastomoses. Under these circumstances, the surviving fetus will rapidly become anemic (ischemic), blood pressure will drop, and brain damage can occur.



Risk of neurological sequelae in twins

Neurological sequelae have the potential to occur in any pregnancy, not just twin pregnancies, as these can result from birth of a premature baby, hypoxia during delivery, or as a result of the underlying diseases of the infant. Naturally, prematurity (especially infants born at a very early number of weeks) or hypoxia during delivery will in and of themselves increase the risk of neurological sequelae. Merely the presence of twins itself does not greatly alter the risk. However, compared to singleton pregnancies, because the probability of premature delivery and extreme immaturity (low birth weight) is higher with twins, the overall incidence of neurological sequelae also increases. It is believed that given the same circumstances (same number of weeks gestation, and body weight, etc.), the risks in twin pregnancies are virtually the same as in singleton pregnancies. As a result, risks can be lowered by preventing preterm labor in twin pregnancies (or even in the case of preterm labor, attempts can be made to maximize the number of weeks of gestation so that the baby is born in good condition). In addition, in monochorionic pregnancies, the risk can be lowered by preventing TTTS and single fetal demise, and to implement the appropriate maintenance therapy even if these do occur.

Perinatal outcomes according to the gestational weeks (reference data)

	≤21 W	22 W	23 W	24 W	25 W	26 W	27 W	28 W
SURVIVAL RATE (%)	0	10-20	30-50	60-80		>95		≈100
WITHOUT SEQUELAE (%)	0	?	?	80		>90		>95

Reference

- De Lia JE, Cruikshank DP, Keye WR, Jr. Fetoscopic neodymium:YAG laser occlusion of placental vessels in severe twin-twin transfusion syndrome. *Obstet Gynecol* 1990;75(6):1046-53.
- De Lia JE, Kuhlmann RS, Harstad TW, Cruikshank DP. Fetoscopic laser ablation of placental vessels in severe previable twin-twin transfusion syndrome. *Am J Obstet Gynecol* 1995;172(4 Pt 1):1202-8; discussion 1208-11.
- Fusi L, McParland P, Fisk N, Nicolini U, Wigglesworth J. Acute twin-twin transfusion: a possible mechanism for brain-damaged survivors after intrauterine death of a monochorionic twin. *Obstet Gynecol* 1991;78(3 Pt 2):517-20.
- Hecher K, Plath H, Bregenzler T, Hansmann M, Hackeloer BJ. Endoscopic laser surgery versus serial amniocenteses in the treatment of severe twin-twin transfusion syndrome. *Am J Obstet Gynecol* 1999;180(3 Pt 1):717-24.
- Huber A, Diehl W, Bregenzler T, Hackeloer BJ, Hecher K. Stage-related outcome in twin-twin transfusion syndrome treated by fetoscopic laser coagulation. *Am J Obstet Gynecol* 2006;108(2):333-337.
- Ishii K, **Murakoshi T**, Hayashi S, Saito M, Sago H, Takahashi Y, et al. Ultrasound predictors of mortality in monochorionic twins with selective intrauterine growth restriction. *Ultrasound Obstet Gynecol*. 2011 Jan;37(1):22-6.
- Ishii K, **Murakoshi T**, Takahashi Y, Shinno T, Matsushita M, Naruse H, et al. Perinatal outcome of monochorionic twins with selective intrauterine growth restriction and different types of umbilical artery Doppler under expectant management. *Fetal Diagn Ther*. 2009;26(3):157-61.
- Ishii K, **Murakoshi T**, Matsushita M, Sinno T, Naruse H, Torii Y. Transitory increase in middle cerebral artery peak systolic velocity of recipient twins after fetoscopic laser photocoagulation for twin-twin transfusion syndrome. *Fetal Diagn Ther*. 2008;24(4):470-3.
- Ishii K, **Murakoshi T**, Hayashi S, Matsuoka K, Sago H, Matsushita M, et al. Anemia in a recipient twin unrelated to twin anemia-polycythemia sequence subsequent to sequential selective laser photocoagulation of communicating vessels for twin-twin transfusion syndrome. *Prenat Diagn*. 2008 Mar;28(3):262-3.
- Ishii K, Hayashi S, Nakata M, **Murakoshi T**, Sago H, Tanaka K. Ultrasound Assessment prior to Laser Photocoagulation for Twin-Twin Transfusion Syndrome for Predicting Intrauterine Fetal Demise after Surgery in Japanese Patients. *Fetal Diagn Ther*. 2007;22(2):149-54.
- Ishii K, **Murakoshi T**, Numata M, Kikuchi A, Takakuwa K, Tanaka K. An experience of laser surgery for fetofetal transfusion syndrome complicated with unexpected fetofetal hemorrhage in a case of monochorionic triamniotic triplets. *Fetal Diagn Ther*. 2006;21(4):339-42.
- Mari G, Roberts A, Detti L, Kovanci E, Stefos T, Bahado-Singh RO, et al. Perinatal morbidity and mortality rates in severe twin-twin transfusion syndrome: results of the International Amnioreduction Registry. *Am J Obstet Gynecol* 2001;185(3):708-15.
- Murakoshi T**, Ishii K, Matsushita M, Shinno T, Naruse H, Torii Y. Monochorionic monoamniotic twin pregnancies with two yolk sacs may not be a rare finding: a report of two cases. *Ultrasound Obstet Gynecol*. 2010 Jun 8;36:384-6.
- Murakoshi T**, Ishii K, Nakata M, Sago H, Hayashi S, Takahashi Y, et al. Validation of Quintero stage III sub-classification for twin-twin transfusion syndrome based on visibility of donor bladder: characteristic differences in pathophysiology and prognosis. *Ultrasound Obstet Gynecol*. 2008 Nov;32(6):813-8.
- Murakoshi T**, Shinno T, Shiojima S, Ueda T, Matsumoto M. Fetoscopic laser photocoagulation of communicating vessels for severe twin-twin transfusion syndrome. *The Ultrasound Review of Obstetrics & Gynecology*. 2006;6(3):141-9.
- Murakoshi T**, Sago H, Hayashi S, Nakata M, Ishii K, Ueda T, et al. Fetoscopic laser photocoagulation of communicating vessels for twin-twin transfusion syndrome: Japanese 2 year's experience and considering Stage 3 sub-classification. *Ultrasound Obstet Gynecol* 2005;26(4):432-3.

Murakoshi T, Quintero RA, Bornick PW, Allen MH. In vivo endoscopic assessment of arterioarterial anastomoses: insight into their hemodynamic function. *J Matern Fetal Neonatal Med* 2003;14(4):247-55.

Murakoshi T, Yamamori K, Tojo Y, Naruse H, Seguchi M, Torii Y, et al. Pulmonary stenosis in recipient twins in twin-to-twin transfusion syndrome: Report on 3 cases and review of literature. *Croat Med J* 2000;41(3):252-6.
Quintero RA, Morales WJ, Mendoza G, Allen M, Kalter CS, Giannina G, et al. Selective photocoagulation of placental vessels in twin-twin transfusion syndrome: evolution of a surgical technique. *Obstet Gynecol Surv* 1998;53(12 Suppl):S97-103.

Nakata M, **Murakoshi T**, Sago H, Ishii K, Takahashi Y, Hayashi S, et al. Modified sequential laser photocoagulation of placental communicating vessels for twin-twin transfusion syndrome to prevent fetal demise of the donor twin. *J Obstet Gynaecol Res.* 2009 Aug;35(4):640-7.

Quintero RA, Morales WJ, Allen MH, Bornick PW, Johnson PK, Kruger M. Staging of twin-twin transfusion syndrome. *J Perinatol* 1999;19(8 Pt 1):550-5.

Quintero RA, Dickinson JE, Morales WJ, Bornick PW, Bermudez C, Cincotta R, et al. Stage-based treatment of twin-twin transfusion syndrome. *Am J Obstet Gynecol* 2003;188(5):1333-40.

Senat MV, Deprest J, Boulvain M, Paupe A, Winer N, Ville Y. Endoscopic laser surgery versus serial amnioreduction for severe twin-to-twin transfusion syndrome. *N Engl J Med* 2004;351(2):136-44.

Sago H, Hayashi S, Saito M, Hasegawa H, Kawamoto H, Kato N, Nanba Y, Ito Y, Takahashi Y, Murotsuki J, Nakata M, Ishii K, **Murakoshi T**. The outcome and prognostic factors of twin-twin transfusion syndrome following fetoscopic laser surgery. *Prenat Diagn.* 2010 Dec;30(12-13):1185-91.

Ville Y, Hyett J, Hecher K, Nicolaides K. Preliminary experience with endoscopic laser surgery for severe twin-twin transfusion syndrome. *N Engl J Med* 1995;332(4):224-7.

名取道也, 田中守, 河野八郎, 石本人士, 森定優, 小林俊文, et al. YAGレーザーを用いた胎盤血管凝固術を施行した双胎間輸血症候群の一例. *日産婦誌* 1992;44:117-120.

村越毅. 【外来診療マニュアル】 周産期 多胎妊娠. 産婦人科の実際. 2010 10;59(11):1812-8.

村越毅. 一絨毛膜双胎の管理 TTTSや一児死亡など重度合併症に対する治療戦略. *医報とやま*. 2010;04(1501):16-9.

村越毅. 【多胎妊娠 母児の管理】 多胎妊娠にみられる胎児発育不全、selective IUGR. *周産期医学*. 2010 03;40(3):337-41.

村越毅. 【周産期医療の向上を目指して 予知・予防・治療とシステムの最前線[産科編]】 治療の進歩 胎内治療の現況 多胎におけるレーザー治療. *母子保健情報*. 2010;05(61):40-5.

村越毅. 【周産期医療と胎盤 最近の話題】 胎盤と疾患 双胎. *周産期医学*. 2010 07;40(7):1120-5.

室月淳, 左合治彦, 林聡, 加藤有美, 難波由喜子, 伊藤裕司, **村越毅**, 石井桂介, 中田雅彦, 高橋雄一郎. 胎児治療 双胎間輸血症候群に対するレーザー手術における新生児合併症 多施設共同調査研究. *日本周産期・新生児医学会雑誌*. 2010 04;46(1):14-6.

北代祐三, 石井桂介, 松下充, 神農隆, **村越毅**, 成瀬寛夫, et al. 双胎妊娠に対する陣痛誘発の有用性と安全性に関する検討. *産婦人科の実際*. 2010 07;59(7):1113-7.

中島紗織, **村越毅**, 神農隆, 松下充, 石井桂介, 成瀬寛夫, et al. 妊娠34週以降の双胎管理における膜性診断別の周産期予後の検討. *聖隷浜松病院医学雑誌*. 2010 06;10(1):48-51.

高橋雄一郎, 左合治彦, **村越毅**, 中田雅彦, 林聡, 石井桂介, et al. 胎児治療 双胎間輸血症候群に対する胎児鏡下胎盤吻合血管レーザー凝固術による母体合併症の検討 多施設共同、後方視的調査研究. *日本周産期・新生児医学会雑誌*. 2009 12;45(4):1229-30.

石井桂介, 村越毅, 松下充, 神農隆, 成瀬寛夫, 鳥居裕一, et al. 胎児治療 胎児鏡下レーザー凝固術の適応拡大に向けた早期発症Selective IUGRの予後因子の検討. 日本周産期・新生児医学会雑誌. 2009 12;45(4):1231-2.

石井桂介, 村越毅, 松下充, 神農隆, 成瀬寛夫, 鳥居裕一. 双胎間輸血症候群での一児胎児死亡症例における胎児輸血 (Intrauterine rescue transfusion)の試み. 日本周産期・新生児医学会雑誌. 2009 04;45(1):147-51.

村越毅. 【Discordant twinの診断と管理】 一絨毛膜双胎におけるDiscordant twin. 産婦人科の実際. 2009 01;58(1):23-8.

村越毅. 【胎児の診断と治療 最近のトピックス】 【治療の最前線】 TTTSレーザー治療 その現状と将来. 臨床婦人科産科. 2009 07;63(7):945-53.

村越毅. 【アウトカムからみた周産期管理】 多胎におけるレーザー治療. 周産期医学. 2009 10;39(10):1375-80.

左合治彦, 林聡, 加藤有美, 難波由喜子, 伊藤裕司, 室月淳, 高橋雄一郎, 中田雅彦, 石井桂介, 村越毅. 胎児治療 双胎間輸血症候群に対するレーザー手術の治療効果. 日本周産期・新生児医学会雑誌. 2009 12;45(4):1226-8.

林聡, 左合治彦, 高橋雄一郎, 石井桂介, 中田雅彦, 村越毅, et al. 双胎間輸血症候群(Ttts)のレーザー治療症例における妊娠32週未満分娩例の検討. 産婦人科の実際. 2008 04;57(4):727-33.

村越毅, 石井桂介, 左合治彦, 林聡, 中田雅彦, 高橋雄一郎, et al. 双胎間輸血症候群に対する胎児鏡下胎盤吻合血管レーザー凝固術:新生児合併症の検討. 産婦人科の実際. 2008 07;57(7):1183-7.

村越毅, 松原茂樹. 産婦人科診療ガイドライン(産科編)の注意点 双胎管理について. 日本産科婦人科学会雑誌. 2008 09;60(9):N-412-N-9.

村越毅. 【周産期臨床検査のポイント】 基本的な検査 胎盤血管吻合の検査. 周産期医学. 2008 12;38(増刊):207-12.

村越毅. 【周産期診療プラクティス】 妊娠 異常妊娠 双胎の管理. 産婦人科治療. 2008 04;96(増刊):588-94.

村越毅. 【周産期脳障害の原因とその予防】 周産期脳障害の要因 多胎と周産期脳障害. 周産期医学. 2008 06;38(6):679-82.

上田敏子, 村越毅, 沼田雅裕, 坪倉かおり, 松本美奈子, 安達博, et al. 双胎の神経学的長期予後 196組の双胎における産科的リスクファクターに関する検討. 日本周産期・新生児医学会雑誌. 2008 04;44(1):20-4.

村越毅. 【画像診断と妊婦管理】 多胎の超音波管理. 産婦人科治療. 2007;94(1):72-8.

村越毅. 【産科超音波診断 正診への道筋】 妊娠初期 多胎妊娠の膜性診断を正確に. 臨床婦人科産科. 2007;61(8):994-1001.

村越毅. 双胎間輸血症候群の管理. 日本産科婦人科学会雑誌. 2007;59(9):N588-N95.

村越毅. 胎児治療の最前線. 本邦における現状と今後の展望. 日本産科婦人科学会神奈川地方部会誌. 2007;44(1):56-62.

村越毅. 【産婦人科診療Data Book】 双胎間輸血症候群. 産婦人科の実際. 2007;56(11):1849-55.

村越毅. 多胎の超音波管理. 産婦人科治療. 2007;94(1):72-8.

村越毅. 多胎妊娠の管理 外来診療のポイントから最近の話題まで. 日本産科婦人科学会沖縄地方部会雑誌. 2006;28:3-13.

中田雅彦, 村田晋, 平野恵美子, 本田梨恵, 砂川新平, 三輪一知郎, 住江正大, 前場進治, 杉野法広, 村越毅, 左合治彦, 林聡, 石井桂介, 高橋雄一郎. 母体・胎児・新生児の心肺機能低下時の反応と対応 双胎間輸血症候群(TTTS)をおこした胎児・新生児の循環機能低下時の対応. 周産期学シンポジウム. 2006(24):77-82.

原季実子, 北本憲永, 鈴木克尚, **村越毅**. 双胎間輸血症候群における胎児外科治療の臨床工学技士の役割. 日本手術医学会誌. 2006;27(3):262-4.

松本美奈子, **村越毅**, 尾崎智哉, 渋谷伸一, 鳥居裕一. 胚盤胞移植と一絨毛膜性多胎妊娠. 産婦実際 2005;54(2):361-3.

村越毅, 上田敏子, 松本美奈子, 神農隆, 安達博, 渋谷伸一, et al. 多胎妊娠の短期および長期予後の検討. 周産期新生児誌 2005;41(4):750-5.

村越毅, 松本美奈子, 林聡, 左合治彦, 中田雅彦, 成瀬寛夫, et al. 受血児に胎児水腫をきたした双胎間輸血症候群stage IVに対する胎児鏡下胎盤吻合血管レーザー凝固術の治療成績. 日産婦誌 2005;57(2):542.

村越毅, 松本美奈子, 上田敏子, 成瀬寛夫, 鳥居裕一. 双胎間輸血症候群における胎児鏡下胎盤吻合血管レーザー凝固術の有用性・合併症に関する臨床的検討. 周産期新生児誌 2004;40:823-9.

村越毅. 周産期画像診断の適応と安全性：胎児内視鏡. 周産期医学 2004;34:895-900.

村越毅, 松本美奈子, 上田敏子, 成瀬寛夫, 鳥居裕一. 双胎間輸血症候群における胎児鏡下胎盤吻合血管レーザー凝固術の有用性・合併症に関する臨床的検討. 周産期新生児誌 2004;40:823-9.

村越毅. 胎児well-beingの評価：ハイリスク症例における胎児診断と医療介入のタイミング ～双胎間輸血症候群 (TTTS) ～. 産と婦 2004;71:1866-72.

村越毅. 双胎間輸血症候群に対する胎児鏡下胎盤吻合血管レーザー凝固術の臨床経験. 産婦実際 2004;53:1907-12.

村越毅. 周産期におよぼすART (assisted reproductive technology) の光と影：多胎妊娠 ～ARTによる多胎妊娠の管理～. 産婦実際 2004;53:1849-57.

村越毅. 産婦人科で行う超音波診断の実際：多胎の超音波管理. 産婦治療 2004;89:561-5.

村越毅. 胎児診断・治療と患児の予後：双胎間輸血症候群に対する胎児鏡下レーザー治療の遠隔成績. 小児外科 2004;36:1551-6.

村越毅. 双胎間輸血症候群 (TTTS) のレーザー治療. 日産婦医会報 2004;55:10-11.

村越毅, 渋谷伸一, 西垣新. 周産期医療よりみた多胎の現状. 産と婦 2003;70:151-7.

村越毅. 多胎妊娠の管理：最近の知見、疾病双胎の管理～双胎間輸血症候群の病態と治療～. 日産婦誌 2003;55:N216-23.

村越毅, 松本美奈子, 渋谷伸一, 東條義弥, 成瀬寛夫, 鳥居裕一, et al. 双胎間輸血症候群における内視鏡下胎盤血管吻合レーザー焼灼術～米国での実情と当院での取り組み～. 聖隷浜松病院医学雑誌 2002;2:3-12.

村越毅. 双胎の画像診断. 産婦治療 2001;83:189-96.

村越毅. 病態および胎児心機能評価よりみた双胎間輸血症候群. 超音波医学 2001;28:J329-30.